


Practical Otology for the Otolaryngologist



Seilesh Babu

CHAPTER 22

Superior Canal Dehiscence Syndrome

Gerard J. Gianoli

INTRODUCTION

Superior semicircular canal dehiscence (SSCD) has been defined as the absence of bone overlying the superior semicircular canal facing toward the dura of the middle cranial fossa.¹ SSCD has been implicated as the cause of a variety of inner ear symptoms including Tullio's phenomenon, pressure induced vertigo, aural fullness, autophony, conductive hearing loss mimicking the presentation of otosclerosis, and fluctuating or progressive sensorineural hearing loss. Additionally, SSCD has also been reported to be asymptomatic. In the past, many patients with SSCD had been misdiagnosed as having otosclerosis, patulous eustachian tubes, middle ear perilymphatic fistulas, or Ménière's disease. Identification of this entity requires a high degree of suspicion, appropriate findings on physical exam, lab testing, and confirmation on high-resolution CT scan. Surgical repair of the SSCD or occlusion of the superior canal has been reported with a high degree of symptom resolution.

INCIDENCE AND ETIOLOGY

The prevalence of SSCD has been found to be much higher in series of analyzed CT scans than on temporal bone histology. Carey et al identified complete absence of bone over the superior canal histologically

in 0.5% of 1000 vertically sectioned adult temporal bones.² There was an additional 1.4% with very thin (<0.1 mm) bone covering the superior canal. Added together, the prevalence of thin or dehiscent superior canals approached 2%. This study also reported that 50% of the SSCD cases had bilateral involvement.

Carey and colleagues² also analyzed 36 infant temporal bones and concluded that the thickness of the bone overlying the superior canal was consistently thin. The thickness of the bone covering the superior canal gradually thickened with age, reaching adult levels by age 3 years. They theorized that the anatomic finding of SSCD was a developmental anomaly, but since clinical symptoms were typically not noted until later in life, a second event such as head trauma or sudden change in intracranial pressure was required to propagate the symptoms found in SSCD patients.

Roberto et al³ used tetracycline staining to investigate the deposition of bone in the dog model at 10, 25, and 50 days of age. This study demonstrated progressive deposition of endochondral and endosteal bone at the superior semicircular canal postnatally. The bone deposition decreased with age. These findings are in agreement with the observations in the study by Carey et al. In a related study, Hirvonen and colleagues⁴ reported a CT study of the thickness of the superior canal in a group of patients with SSCD and those without SSCD. Among those with SSCD, the contralateral superior canal bone was thinner (or dehiscent), compared to those patients without SSCD. This finding supports the notion of

SSCD as a developmental anomaly related to bony deposition in early life.

Several observations point to a "second event" required to produce symptoms from SSCD. Among these observations are:

1. The above studies demonstrating development of bone over the superior semicircular canal occurring later (postnatally) than other parts of the inner ear.
2. The clinical observation of the presence of asymptomatic SSCD noted during intraoperative exploration of the middle cranial fossa for encephalocele repair.
3. Symptoms from SSCD do not generally present in the pediatric population.

These observations support the notion that a second event is required in addition to the congenital anomaly of thin or absent superior canal bone in order to produce clinical symptoms. Roughly half of patients report an event they attribute to symptom onset for SSCD. This "second event" is typically noted to be either head trauma or a Valsalva type episode.

CLINICAL PRESENTATION

SSCD was first reported by Minor et al¹ in 8 patients who exhibited the symptoms of short-lived vertigo spells in response to certain sounds or activities that would cause transient increases in intracranial or middle ear pressure (Valsalva, coughing, sneezing, nose-blowing, autoinsufflations). These activities would produce a torsional nystagmus, which directly implicated stimulation of the superior semicircular canal. Activities causing increased middle ear pressure (sound, positive pressure in the ear canal, autoinsufflations) induce nystagmus with the slow phase upward and the superior pole of the eye directed *away* from the affected ear. Activities causing a transient elevation in intracranial pressure (Valsalva against a closed glottis, jugular venous compression) or negative pressure in the ear canal resulted in the slow phase of nystagmus directed

downward and the superior pole of the eye torquing *toward* the affected ear. The clinical findings of Tullio's phenomenon and pressure inducing nystagmus associated with SSCD has been termed Minor's syndrome. Although the vertigo caused by SSCD is most characteristically reported as short-lived, other characterizations of vestibular symptoms have been reported as well, including more prolonged vertigo spells, chronic disequilibrium, and drop attacks.

Since the first identification of SSCD as a cause for Minor's syndrome, other symptoms and clinical presentations have been identified.⁵ In a recent review of their experience with SSCD, Zhou et al⁶ described SSCD as a "great otologic mimicker" because of the variety of presentations and the variety of other diagnoses from which SSCD can be confused. SSCD can present with a variety clinical findings that can make distinction from other otologic entities a challenge. Among the otologic entities of which SSCD is most frequently misdiagnosed are Ménière's disease, otosclerosis, perilymphatic fistula, and patulous eustachian tube.

Symptoms noted with SSCD, include vertigo/dizziness induced by sound stimuli or pressure altering activity. Some patients may find no specific exacerbating stimuli. Another symptom is autophony, or hearing one's own voice and breathing. Other symptoms include hearing loss, aural fullness, and tinnitus (pulsatile and nonpulsatile).

PATHOPHYSIOLOGY

The "third mobile window theory" has been proposed to explain the symptoms accompanying SSCD.⁷ This theory proposes that the flexible nature of the SSCD allows for egress of endolymph out of the superior canal resulting in abnormal stimulation of the superior canal cupula. Additionally, low frequency sound energy transmitted through the inner ear is allowed to dissipate through this bony defect resulting in the conductive gap noted in some SSCD patients. Merchant and Rosowski⁸ proposed that SSCD could be classified among a number of lesions that produce a third mobile window on the scala vestibuli side of the cochlea. Included among these are

lateral or posterior canal dehiscence, enlarged vestibular aqueduct, dehiscence of the internal auditory canal, carotid dehiscence (into the cochlea), diffuse dehiscence (such as in Paget's disease), and other congenital anomalies of the inner ear. The hearing loss in these pathologic third mobile window cases exhibits poor air conduction thresholds and good bone conduction thresholds.

The above theories do not completely explain all of the findings of SSCD. Among these is the presence of asymptomatic patients, the presentation of patients with only auditory and no vestibular findings or vice versa, Ménière's-type vertigo spells, and the absence of symptoms in the pediatric population. It has been proposed that a second event such as trauma or a major pressure-altering event (Valsalva-type maneuver) causes a disruption of very thin bone over the superior canal thus creating an SSCD. However, this only explains adult onset of symptoms and not the other findings, nor does it explain a true dehiscence in an asymptomatic patient. Gianoli and Soileau⁹ proposed the theory that alteration of intracranial pressure resulted in increased compliance at the round and oval windows and, if pressure changes were extreme, potential disruption of the windows resulting in a frank middle ear perilymph fistula. This theory could explain the above exceptions to the third mobile window theory and also explain why round window reinforcement has been noted to resolve SSCD symptoms (at least temporarily) in many patients. They further proposed a grading system for SSCD as listed in Table 22-1.

Table 22-1. Staging System for SSCD

Stage 1: Asymptomatic SSCD—atomic dehiscence with no inner ear symptoms.
Stage 2: Minor's syndrome—Tullio's phenomenon and Valsalva induce vertigo, correlating with an increased compliance of the inner ear system.
Stage 3: Ménière's syndrome—vertigo and hearing loss mimicking Meniere's disease, correlating with a frank oval or round window fistula.
Stage 4: End stage—profound hearing loss or vestibular areflexia, reflecting an end stage to the damage from stage 3.

EVALUATION

In SSCD, the hearing loss most frequently cited is a conductive hearing loss resembling that of otosclerosis. SSCD can be differentiated from otosclerosis by impedance testing and pure tone testing at lower sensation levels than routine testing.⁸ Often, if tested for, the SSCD patients are noted to have sensorineural scores with sensation levels much better than the norm (eg, -5 or -10 dB). Additionally, impedance testing reveals that the acoustic reflexes are intact among SSCD patients, which is in contradistinction to the otosclerotic patient whose acoustic reflexes should be absent. Although most papers regarding patients with SSCD report normal hearing or a low frequency conductive hearing loss, there are some reports of sensorineural hearing loss.

Impedance testing can also be helpful in excluding eustachian tube dysfunction and patulous eustachian tube as the etiology for autophony or aural fullness in SSCD patients. Additionally, the absence of TM excursion with respiration would tend to exclude patulous eustachian tube as the diagnosis.

Examination of the eyes with various manipulations (preferably with means of magnification and prevention of fixation such as with infrared video goggles) can often produce the above-mentioned characteristic nystagmus found in SSCD. Testing with loud sounds in the affected ear (Tullio's phenomenon) appears to be a specific but not very sensitive finding in SSCD. Characteristic nystagmus associated with either autoinflation, Valsalva with a closed glottis or traditional fistula testing (applying both negative and positive pressure) appears to be more commonly present in SSCD patients.

Additional testing that has been useful in the confirmation of SSCD is Vestibular Evoked Myogenic Potentials (VEMP).^{6,10} Several studies have identified abnormally low thresholds on VEMP testing in cases of SSCD (defined as ≤ 65 dB). According to one study this appears to be a more sensitive test for SSCD than the previously mentioned tests and the authors reported 91.4% sensitivity and 95.8% specificity for the diagnosis of SSCD.

Another proposed screening test included suboccipital vibration, reported by White and colleagues.¹¹

In their study of 8 SSCD patients, application of 100-Hz vibration to the ipsilateral suboccipital region produced vertical/torsional nystagmus in all 8 patients. Although, this appears to be a very sensitive the specificity may be lacking since vibration induced nystagmus is present in many peripheral vestibular disorders.

IMAGING

Although SSCD is suspected by history, physical findings, and testing, radiographic imaging is required to confirm its presence. High-resolution CT scan has been the imaging modality of choice. Sub-millimeter cuts are required for adequate imaging. Cuts of 1.0 mm or larger are inadequate and will lead to an overly high false-positive rate of diagnosis. Among reports of CT scan findings of SSCD, Williamson et al¹² identified SSCD in 9% of coronal CT scans with 1.0 mm collimation performed at their institution over a 2-year period. Cloutier et al¹³ found

a 4% incidence of SSCD findings on CT scans with 0.55 mm collimation and reformatting in the plane of the superior canal among 581 temporal CT scans performed over a one-year period. Consistent with these findings, Belden et al¹⁴ found an improved positive predictive value for SSCD with 0.5 mm collimation compared to 1.0 mm collimation. Both of the above mentioned studies of SSCD incidence are much higher than the 0.5% of histologically identified SSCD by Carey et al. The discrepancy of SSCD findings between 1.0-mm and 0.5-mm scans can be accounted for by averaging artifact. However there is still a significant difference between incidence of SSCD on the 0.5-mm CT study and on the histologic study. This is likely due to a combination of the averaging artifact in patients with very thin bone and study selection bias. When evaluating temporal bone CT scans for SSCD it is prudent to ensure the presence of the dehiscence on more than one image series (Figure 22-1).

Consequently, the finding of SSCD on temporal bone CT by itself does not necessarily implicate SSCD as the cause for the patient's symptomatol-

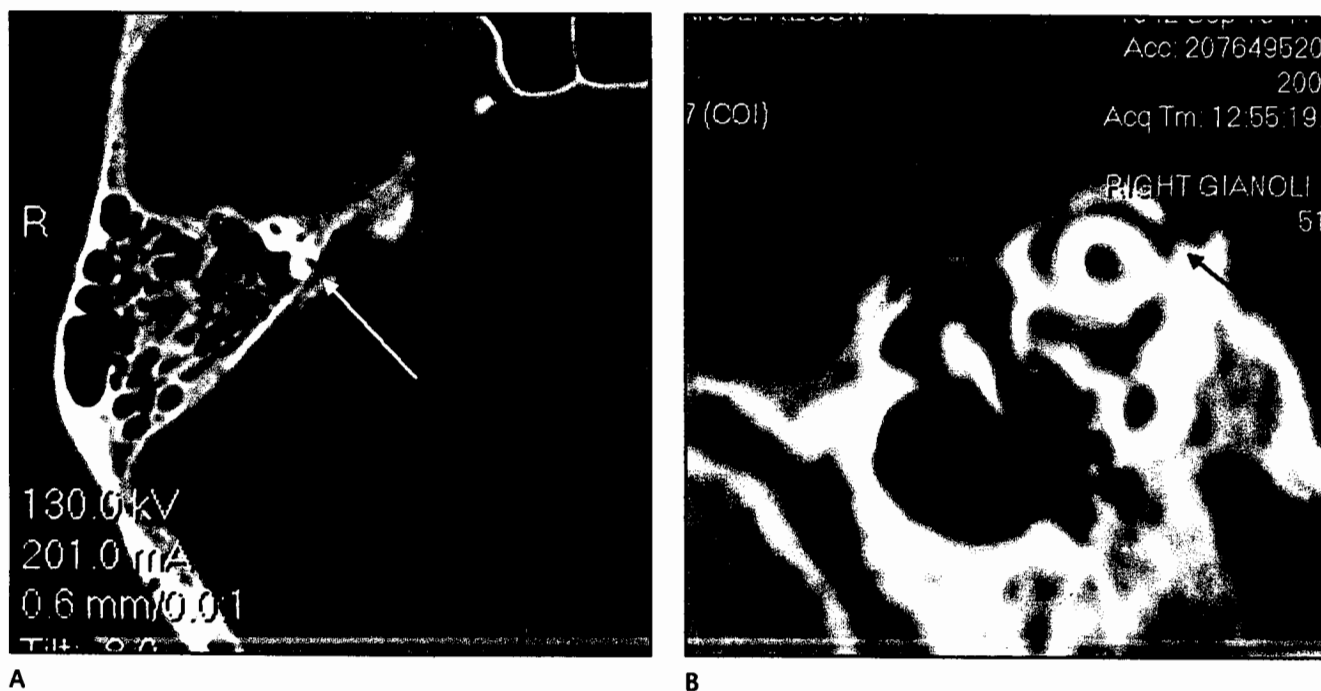


Figure 22-1. A. Axial CT demonstrating SSCD at the site of the superior petrosal sinus. B. CT reconstruction in the plane of the superior canal demonstrating the corresponding dehiscence at the superior petrosal sinus.

ogy. Even with currently available technology, there is still a small false positive rate for SSCD diagnosis. Additionally, SSCD has been reported as an asymptomatic entity. In order to presume a causative role for SSCD in the patient's inner ear pathology, corroboration with an appropriate history, physical examination, and vestibular testing is mandatory. It should also be noted that dehiscence of the posterior semicircular canal can cause clinical symptoms very similar to SSCD, so the posterior canal integrity should be assessed during temporal bone imaging in suspected SSCD cases.

With the current multislice scanners, the images can be reformatted to slice into virtually any plane

the examiner wishes. The author finds that planar cuts parallel and perpendicular to the superior canal very helpful. However, cuts that are radially sent out like wheel spokes from a central point located at the arcuate artery are probably the most useful, as all the images are always roughly a perpendicular cut through the superior canal (Figure 22-2). It should be noted that a contralateral SSCD is present in approximately 50% of patients and that the superior canal bone is often very thin in the rest of the patients.

The concept of the "dehiscent middle fossa" has been put forward with regard to more global anomalies of the middle fossa in patients with SSCD.¹⁵ The

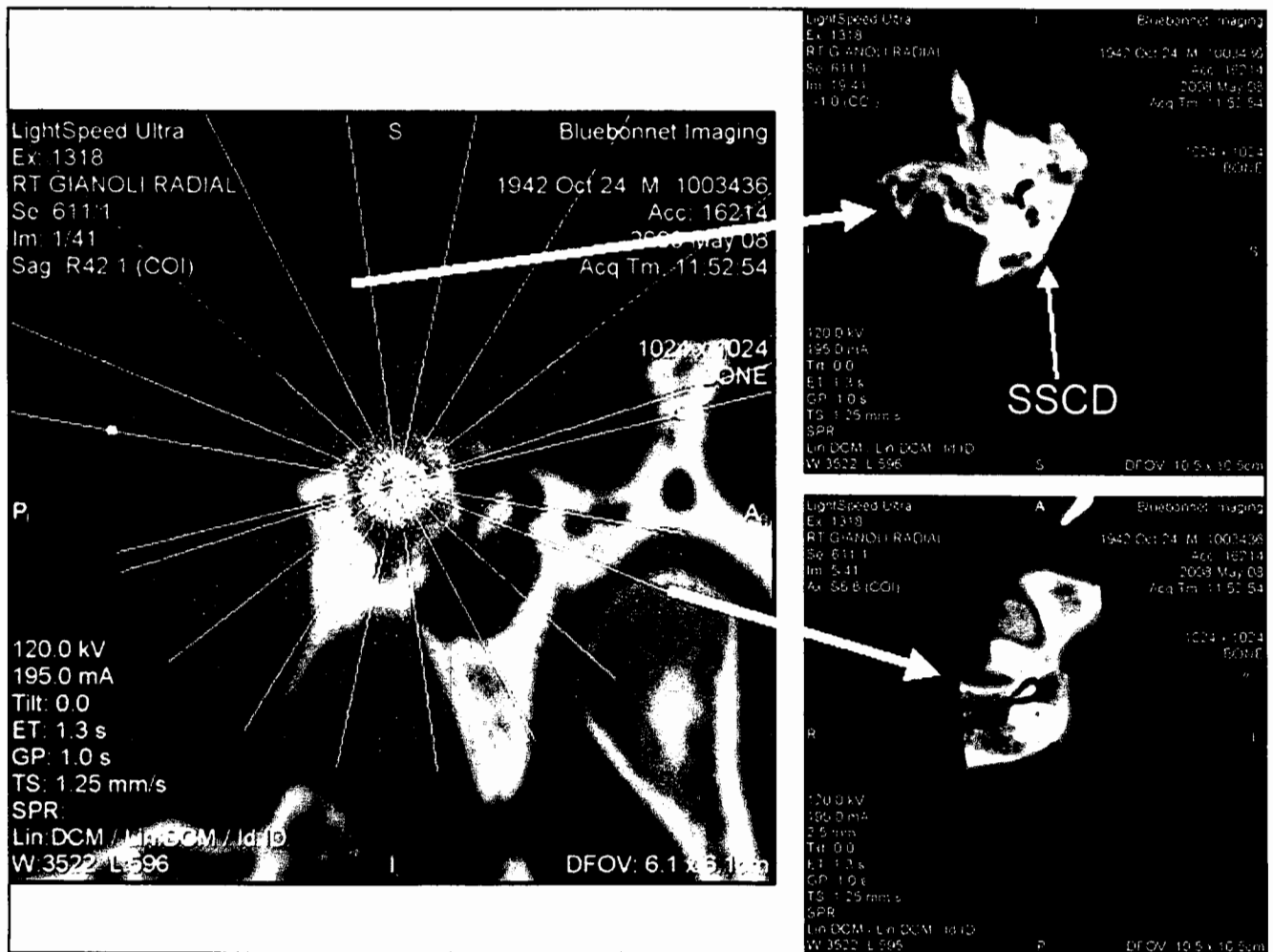


Figure 22-2. On the left, scout of CT reconstructions performed in a radial manner centered on the subarcuate artery. On the right are two corresponding slices from this construct.

constellation of findings in the dehiscent middle fossa includes SSCD, multiple tegmen defects, geniculate ganglion dehiscence, and encephaloceles. Even a case of bilateral dehiscent internal auditory canals has been seen by this author. The incidence of multiple tegmen defects is normally about 20% among random temporal bones studied. However, multiple tegmen defects are present in roughly 80% of patients with SSCD. With a higher incidence of multiple tegmen defects, encephaloceles are encountered more frequently in this patient population. Consequently, CT imaging in cases of temporal bone encephaloceles should include scrutiny of the superior canal for dehiscence since this would be important for surgical planning (Figure 22-3). Similarly, bony dehiscence of the geniculate ganglion is found in 5 to 15% of random temporal bones but has been found in 53% of SSCD temporal bones (Figure 22-4). This obviously has implications for surgical planning.

TREATMENT

Although surgical repair or occlusion has been the thrust of almost all reports to date regarding SSCD, it should be noted that many patients with SSCD do not require any intervention. Surgical intervention is generally reserved for patients who have significant symptoms who cannot be managed with supportive medical care. Surgical options include repair of the SSCD or occlusion of the superior canal through either a middle fossa craniotomy approach or a transmastoid approach, transcanal reinforcement of the oval and round windows and, lastly, a combination of oval/round window repair with repair of the SSCD.

Most of the reports in the literature describe the middle fossa approach for either repair or occlusion (Figure 22-5). With this approach, a standard middle fossa craniotomy is performed. During temporal

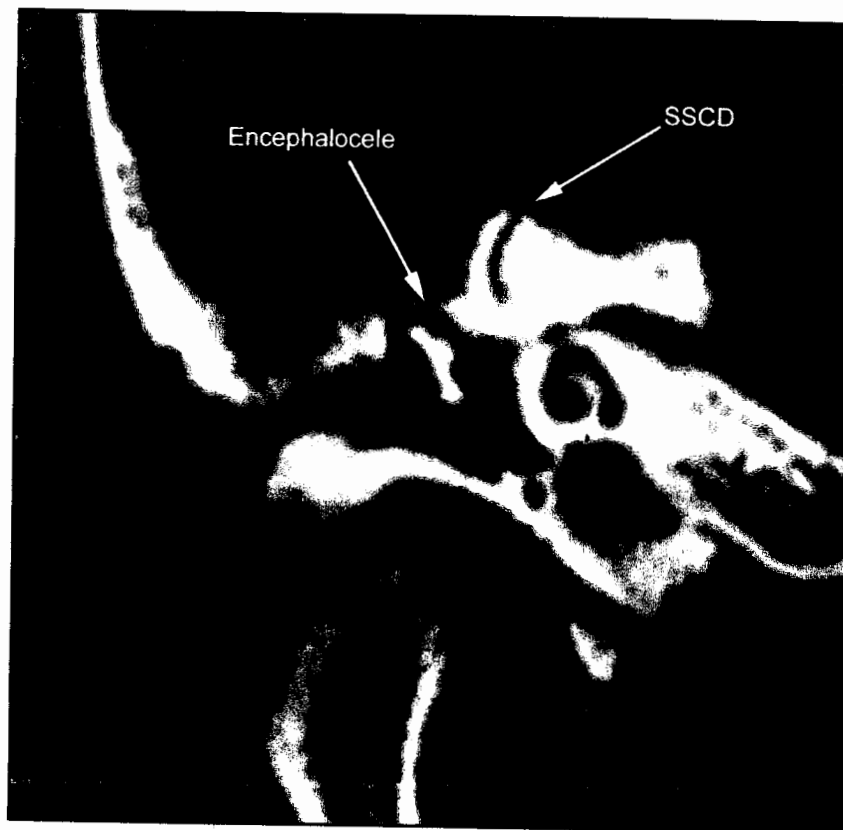


Figure 22-3. Coronal CT scan in a case of an encephalocele with concomitant SSCD.

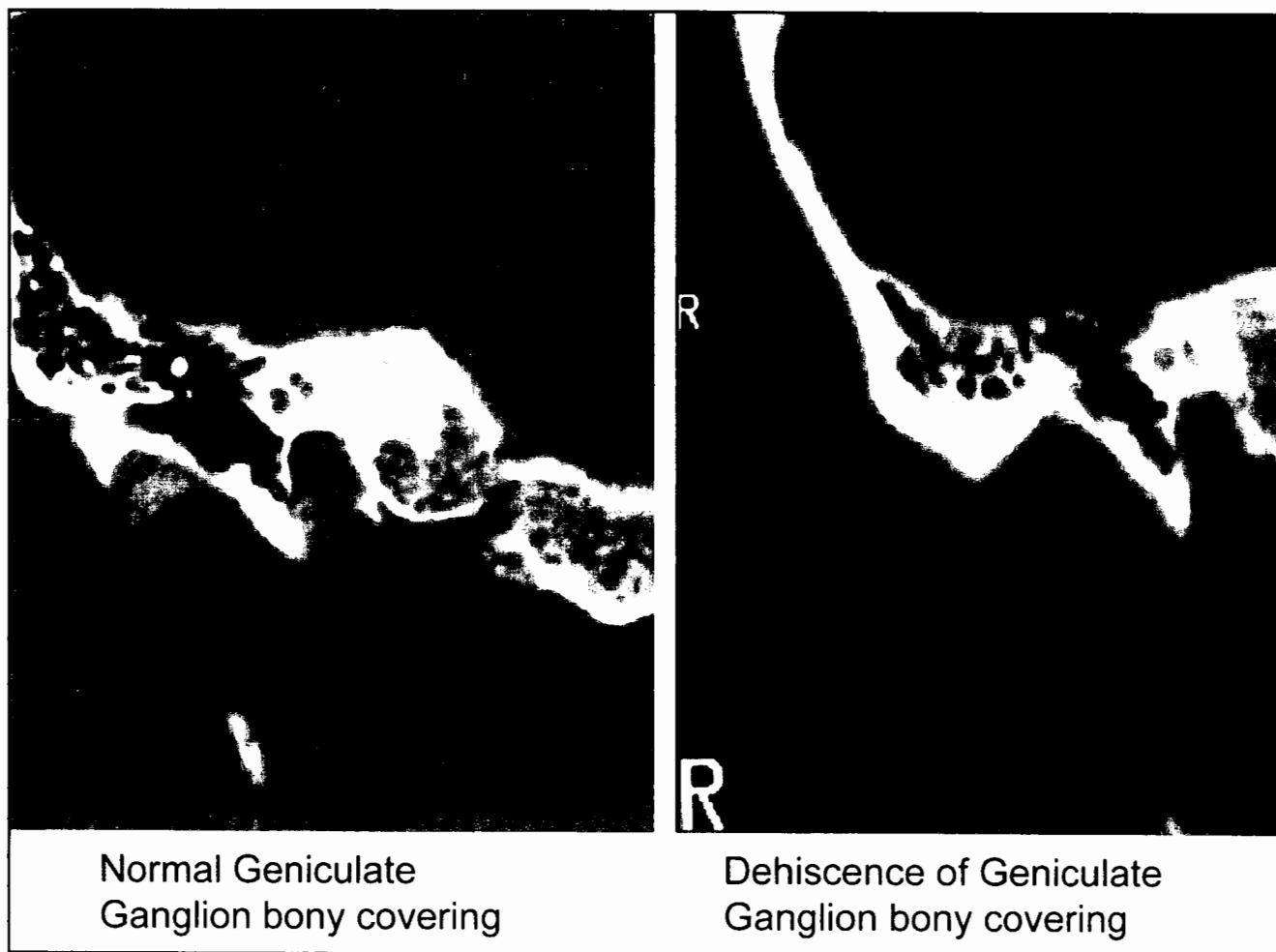


Figure 22-4. Coronal CT scans of normal bony covering of the geniculate ganglion in a non-SSCD patient (*left*) and a dehiscence geniculate ganglion in an SS CD patient (*right*).

lobe retraction care is taken to not inadvertently suction or otherwise breach the SS CD. Localization of the SS CD can sometimes be difficult due to multiple dehiscences of the tegmen that are frequently seen in this patient population. In these cases, image guided navigational systems have proven helpful. Additionally, due to the greater incidence of dehiscence of the geniculate ganglion, it is recommended that dissection proceed with facial nerve monitoring and facial nerve stimulating dissectors. Once the dehiscence is identified, repair or occlusion may be performed. Occlusion can be performed with bone wax or fascia. The author favors repair of the defect with a small piece of calvarial bone obtained from

the craniotomy flap, which is fixed into place with hydroxyapatite bone cement (Figure 22-6).

In transmastoid occlusion of SS CD, a standard mastoidectomy is performed. Dissection is carried superior to the horizontal canal and the superior canal is identified at its anterior limb. The superior canal can then be blue-lined and opened for occlusion. Occlusion of the superior canal in this case proceeds similarly to a posterior canal occlusion surgery for intractable BPPV. However, it should be noted that the anatomy of many SS CD patients is such that the tegmen is particularly low-lying. This makes transmastoid occlusion technically more challenging in these patients.

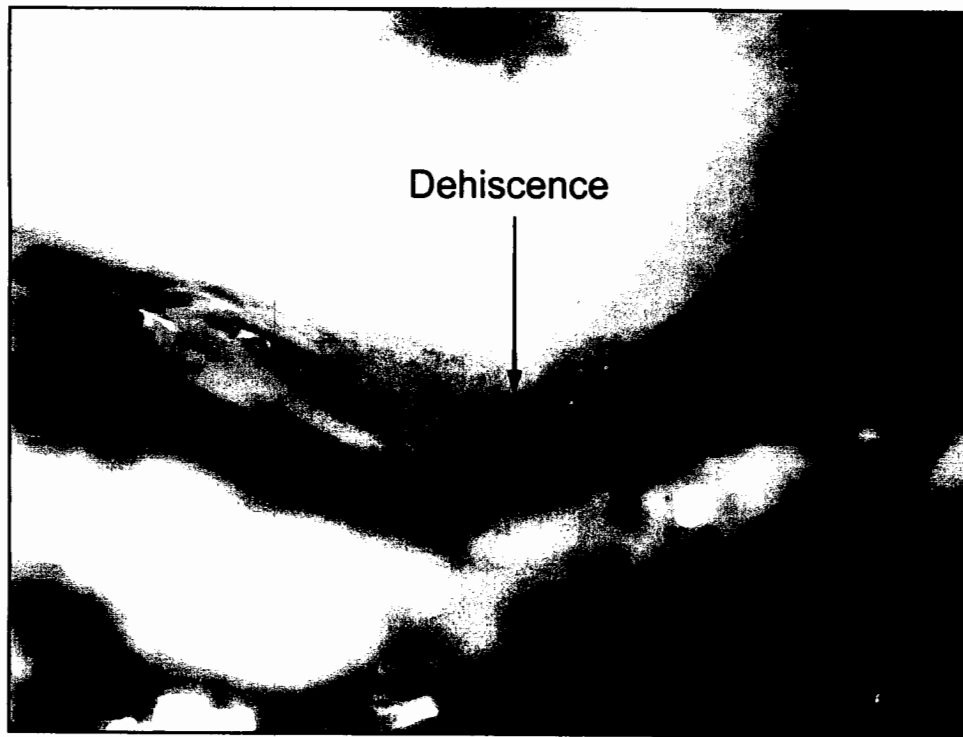


Figure 22–5. Intraoperative photograph of an SSCD as seen through the middle fossa approach.

As advocated by Kartush,¹⁶ the transcanal approach to reinforce the oval and round windows is based on the idea of limiting the compliance of the inner ear system by reducing the mobility of the middle ear windows. This procedure was first performed for SSCD unknowingly by surgeons attempting to repair oval/round window perilymphatic fistulas. In some patients this produced long-lasting resolution of symptoms. However, there are no published studies to date to report overall success rate. The author and others have used this approach with selected SSCD patients. The author's impression is that the success rate is much lower than repair/occlusion but it does offer a more minimally invasive approach with significantly less risk to the patient. This procedure is virtually identical to the traditional routine oval window and round window repair for middle ear perilymphatic fistula. Some have advocated using a cartilage graft to reinforce the round window repair and others have advocated the use of fibrin glue and extensive middle ear packing with Gelfoam.

A combined approach of middle fossa repair of the SSCD and oval/round window reinforcement has been reported by Gianoli and Soileau,⁹ who compared the outcomes of patients undergoing middle fossa repair and combined middle fossa repair with oval/round window repair. Although all patients had resolution of vertigo, outcome from the combined procedure was felt to be superior to middle fossa repair alone.

Surgical repair and/or occlusion have been reported to resolve vertiginous symptoms of SSCD with a high degree of reliability. In the few cases reported that have had failure of repair or occlusion, revision surgery appears to be successful. No published studies are available for the outcome of the minimally invasive oval/round window reinforcement approach. Although it appears successful in some isolated cases, the overall success in a large patient population is not known, nor is the long-term resolution rate.

Complications from the above mentioned surgeries are what one would expect from similar neuroto-

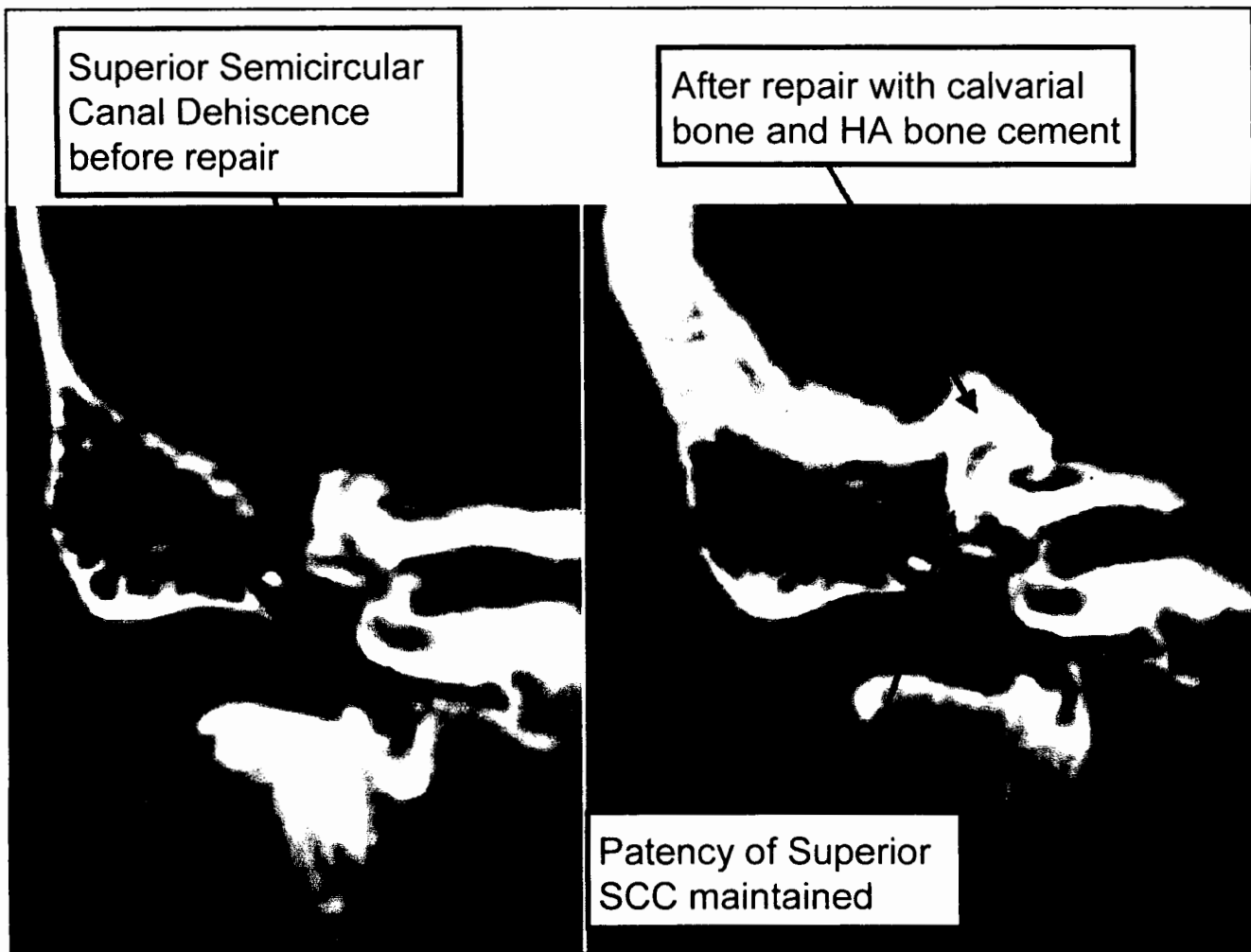


Figure 22-6. Preoperative (*left*) and postoperative (*right*) coronal CT scans in a patient who underwent middle fossa repair of SSCD with calvarial bone and HA bone cement. Note that patency of the superior canal is maintained and it is easily imaged postoperatively.

logic procedures using the same approaches. The loss of superior semicircular canal function is an expected outcome in the occlusion technique; however, loss of global vestibular function and sensorineural hearing loss has also been reported. Failure due to either misplaced bone grafts in the repair technique and inadequate plugging in the occlusion technique can occur.

REFERENCES

1. Minor LB, Solomon D, Zinreich JS, Zee DS. Sound- and/or pressure-induced vertigo due to bone dehiscence of the superior semicircular canal. *Arch Otolaryngol Head Neck Surg.* 1998;124:249-258.
2. Carey JP, Minor LB, Nager GT. Dehiscence or thinning of the bone overlying the superior semicircular canal in a temporal bone survey. *Arch Otolaryngol Head Neck Surg.* 2000;126(2):137-147.
3. Roberto M, Favia A, Lozupone E. Postnatal bone growth in the semicircular canals of the dog. *Ital J Anat Embryol.* 1998;103:27-34.
4. Hirvonen TP, Weg N, Zinreich SJ, Minor LB. High-resolution CT findings suggest a developmental abnormality underlying superior canal dehiscence syndrome. *Acta Otolaryngol.* 2003;123(4):477-481.
5. Smullen JL, Andrist EC, Gianoli GJ. Superior semicircular canal dehiscence: a new cause of vertigo. *Journal LA State Med Soc.* 1999;151:397-400.

6. Zhou G, Gopen Q, Poe DS. Clinical and diagnostic characterization of canal dehiscence syndrome: a great otologic mimicker. *Otol Neurotol*. 2007;28(7):920-926.
 7. Minor LB. Superior canal dehiscence syndrome. *Am J Otol*. 2000;21:9-19.
 8. Merchant SN, Rosowski JJ. Conductive hearing loss caused by third window lesions of the inner ear. *Otol Neurotol*. 2008;29:282-289.
 9. Gianoli GJ, Soileau JS. *The dehiscence middle fossa: prevalence, manifestations, associated findings and results of 24 surgical explorations for superior semicircular canal dehiscence*. Presented as a Triologic thesis, publication pending. 2005.
 10. Brantburg K, Bergenius J, Tribukait A. Vestibular-evoked myogenic potentials in patients with dehiscence of the superior semicircular canal. *Acta Otolaryngol (Stockh)*. 1999;119:633-640.
 11. White JA, Hughes GB, Ruggieri PN. Vibration-induced nystagmus as an office procedure for the diagnosis of superior semicircular canal dehiscence. *Otol Neurotol*. 2007;28(7):911-916.
 12. Williamson RA, Vrabec JT, Coker NJ, Sandlin M. Coronal computed tomography prevalence of superior semicircular canal dehiscence. *Otolaryngol Head Neck Surg*. 2003;129(5):481-485.
 13. Cloutier JF, Belair M, Saliba I. Superior semicircular canal dehiscence: positive predictive value of high-resolution CT scanning. *Eur Arch Otorhinolaryngol*. 2008;265(12):1455-1460.
 14. Belden CJ, Weg N, Minor LB, Zinreich SJ. CT evaluation of bone dehiscence of the superior semicircular canal as a cause of sound- and/or pressure-induced vertigo. *Radiology*. 2003;226(2):337-343.
 15. Gianoli GJ. Deficiency of the superior semicircular canal. *Curr Opin Otolaryngol Head Neck Surg*. 2001;9:336-341.
 16. Kartush JK. *Superior canal dehiscence syndrome symptoms resolved by reinforcement of the oval and round windows*. Unpublished data. 2002.
-